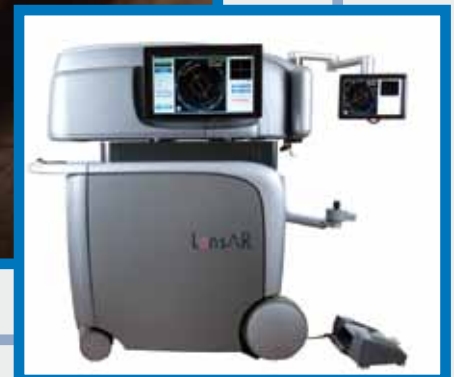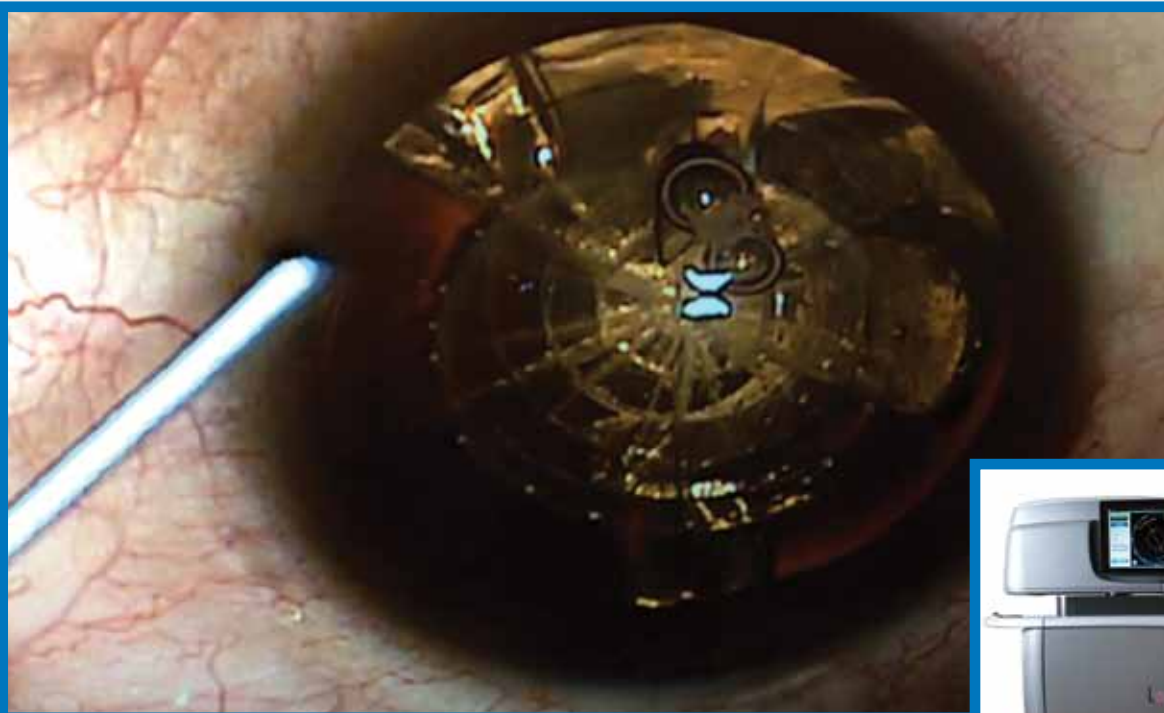


# Cataract & Refractive Surgery

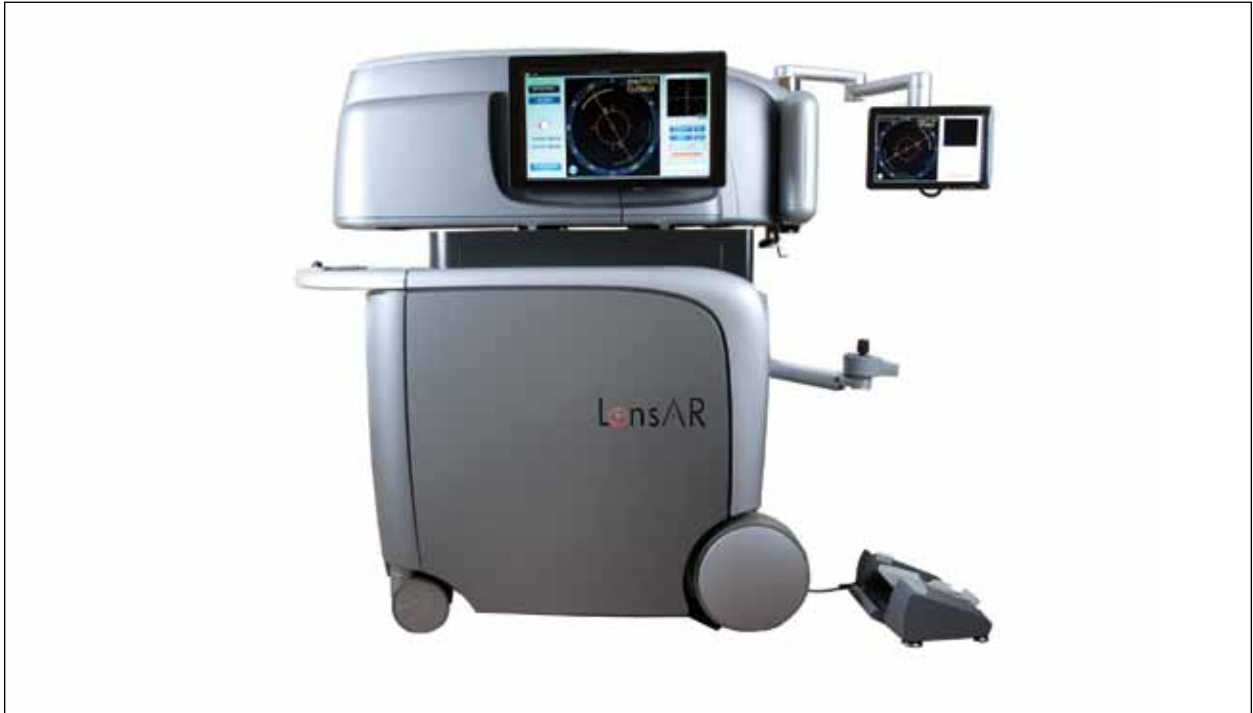EUROPE

TODAY

## THE NEXT STANDARD IN LASER REFRACTIVE CATARACT SURGERY



# The Next Standard in Laser Refractive Cataract Surgery



## Table of Contents

<b>APPLICATIONS OF THE LENSAR LASER SYSTEM FOR REFRACTIVE CATARACT SURGERY.....</b>	<b>3</b>
<i>BY MARK PACKER, MD, FACS, CPI</i>	
<b>LASER CATARACT SURGERY WITH THE LENSAR SYSTEM.....</b>	<b>7</b>
<i>BY HARVEY SIY UY, MD</i>	
<b>LEARNING THE LENSAR APPROACH TO FEMTOSECOND LASER CATARACT SURGERY .....</b>	<b>11</b>
<i>BY MIGUEL A. ZATO, MD, PhD; AND ALFONSO ARIAS, MD, PhD</i>	
<b>FIRST IMPRESSION OF LASER CATARACT SURGERY.....</b>	<b>13</b>
<i>BY DETLEF HOLLAND, MD</i>	
<b>LASER CATARACT SURGERY AND PHACO TIME .....</b>	<b>14</b>
<i>BY SUNIL SHAH, FRCOPHTH, FRCS(Ed), FBCLA</i>	

# Applications of the LensAR Laser System for Refractive Cataract Surgery

With functions for anterior capsulotomy, lens fragmentation, and corneal cuts, this technology produces reproducible and reliable results.

BY MARK PACKER, MD, FACS, CPI

Femtosecond lasers have a unique ability to create small and discreet photodisruptions of tissue with minimal collateral effects. When applied to ocular tissue, this disruption enables very precise cutting in the cornea, lens capsule, and the crystalline lens itself (Figure 1). Laser-assisted refractive cataract surgery using femtosecond lasers has become the most recent disruptive technology to reach the cataract surgeon, and it has several applications, which are discussed at length below. The femtosecond lasers currently being brought to market are indicated for:

- anterior capsulotomy;
- lens fragmentation; and
- partial and full thickness corneal cuts with applications for refractive keratectomy and surgical incisions.

## ANTERIOR CAPSULOTOMY

### Precision and reproducibility of intended diameter.

Laser capsulotomy brings precision and reproducibility to the process of creating a capsular opening. Studies have shown that laser capsulotomies are significantly closer to their intended diameter than manual continuous curvilinear capsulorhexes (CCCs).<sup>1,2</sup> In these and other published studies, differences in the measured deviations from the intended diameter have been seen; however, they reflect the method for which the outcomes were measured. In some studies, researchers attempted to measure the capsular opening where an arbitrary correction was made for anterior chamber depth and refractive index of the aqueous humor. In others, balanced saline solution was present at time of measurement or the measurement extended beyond the removed capsular button, which may have undergone changes due to variations in hydration and/or mechanical changes from the cutting of the capsule fibers.




Figure 1. Scanning electron microscopy of the effect of a single laser pulse on a crystalline lens fiber.

Naranjo Tackman<sup>1</sup> reported on buttons removed from cataract patients and compared the deviation from intended capsulotomy diameter with a laser system with that obtained with a manual CCC. The laser capsulotomies were significantly closer to the intended diameter (Table 1). Figure 2 shows a typical button retrieved after laser capsulotomy, illustrating the regular spherical shape obtained.

Friedman et al<sup>2</sup> reported on a similar series. Here, the analysis of button diameter was based on the mean of just four diameters across the button. They reported a mean deviation from intended diameter of 29  $\mu\text{m}$  for laser capsulotomy and 337  $\mu\text{m}$  for manual CCCs.

**Factors affecting anterior capsulotomy.** One of the most significant factors influencing the capsulotomy is the degree of lens tilt relative to the axis of the laser. This may be occasioned by true anatomical tilt or by apparent tilt due to asymmetrical docking. If the capsulotomy

TABLE 1. CAPSULOTOMY DATA BY GROUP (DIFFERENCES ARE SIGNIFICANT; P=.03).

Group	Capsulotomy/Capsulorrhexis Diameter (mm)		
	Attempted	Measured	Attempted-Achieved
<b>Laser (n=49)</b>			
Mean	5.23	5.08	0.16
SD	0.06	0.18	0.17
<b>CCC (n=24)</b>			
Mean	5.36	4.95	0.42
SD	0.55	0.53	0.54

CCC = continuous curvilinear capsulorrhexis / SD = standard deviation

Photo courtesy of LensAR, Inc.




Figure 2. Typical capsule button created by femtosecond laser capsulotomy, demonstrating regularity of shape.

is cut normal to the tilted capsule, it will break out of the capsule on one side before the other, directly leading to a tag and indirectly leading to an anterior tear. In a paper describing early experience with the LenSx Laser System (Alcon Laboratories, Inc.), for instance, Bali et al<sup>3</sup> indicated that 10.5% of laser capsulotomies had anterior tags and only 17.5% were free floating. Anterior radial tears occurred in 8.4% of cases in this series.

In the early development of the LensAR Laser System (LensAR, Inc.), asymmetrical docking occurred in some cases. However, the commercial version of the system available today incorporates a measurement of and correction for lens tilt such that the capsulotomy is always cut tangential to the capsule surface. In other words, it is tilted to match the tilt of the capsule. This function is possible due to high-quality imaging derived from the LensAR Laser System's proprietary 3-D confocal structured imaging system (3D-CSI), biometry, and laser-guidance software. The addition of such components has resulted in a lack of tags and anterior tears to date, and free-floating capsulotomies occur in 92% of cases.<sup>4</sup> Figure 3 shows a case where the capsulotomy is being cut on a tilted lens, as seen on the top right-hand window (highlighted in red).

**Importance of the capsulotomy.** The capsulotomy and its relationship to IOL implantation have a significant influence on the final resting position of the lens. Because the centration of the capsulotomy influences the centration of the IOL, placement of the capsulotomy is important. The LensAR Laser

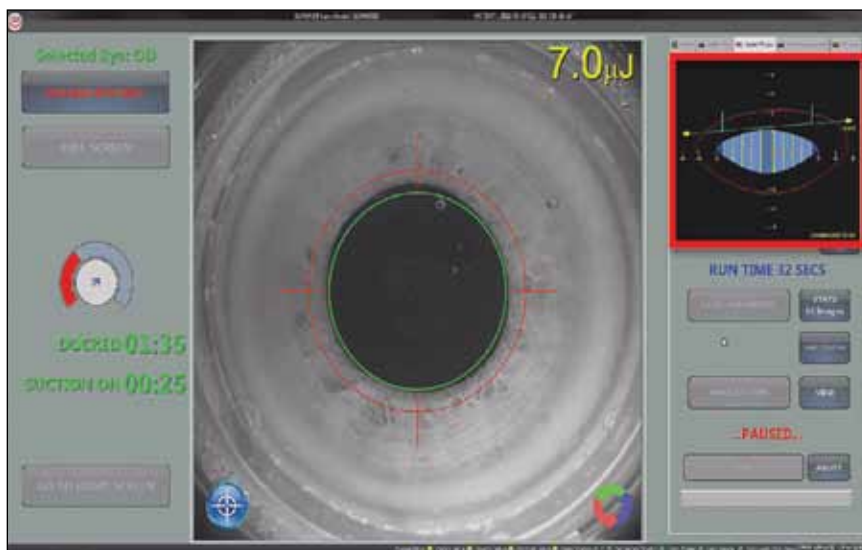


Figure 3. System screen showing the tilted capsulotomy matching the lens tilt determined by the software.

**TABLE 2. PERCENTAGE OF CASES ACHIEVING THE REQUIRED REFRACTIVE OUTCOME**

Results at 6 months postoperative		
Deviation	Laser	Manual
0.00 D	11.6%	4.1%
≤0.50 D	78.7%	52.8%
≤1.00 D	93.2%	90.2%

System offers the option to center the capsulotomy over the pupil center (which is typically where a manual CCC is placed) or over the optical axis of the crystalline lens. The latter option will place the optical axis of the IOL in the same position as that of the crystalline lens being removed (assuming centration of the lens within the bag) and is least likely to cause avoidable induced optical aberrations.

Additionally, the size of the capsulotomy can influence the progression of posterior capsular opacification, with current practice requiring the capsulotomy to come in contact with the optic of the IOL around its circumference. However, significant variations in the extent of contact as well as any area where there is no contact may cause the lens to decenter and/or tilt as the capsule contracts after the surgery. This will influence the postoperative refractive outcome, which is increasingly important especially for premium IOLs. Kranitz et al<sup>5</sup> and Nagy et al<sup>6</sup> reported improved overlap of the capsulotomy edge on the optic of the IOL and less horizontal decentration of the IOL in cases where laser capsulotomy had been used.

It has also been proposed that the consistency of laser capsulotomy may increase the consistency of effective lens position (ELP) and, hence, the ability to hit the target postoperative refractive result. Data presented by Edwards et al<sup>7</sup> confirm this effect and demonstrate that the improvement is consistent with theoretical calculations. In his study of 249 cases undergoing laser capsulotomy and 123 cases undergoing manual CCC, a significantly higher proportion produced the intended refractive outcome at 6 months by a factor of three (Table 2). These data support the theory that laser capsulotomy has a positive effect on consistency of ELP. To improve achievement of intended results further, attention must be paid to biometry, keratometry, and IOL power intervals.

## CORNEAL INCISIONS

The application of femtosecond lasers for corneal surgical incisions is less documented in the literature.

**Architecture.** In an early study with cadaver eyes, Masket et al<sup>8</sup> showed the ability of single-plane laser incisions to be self-sealing at significant intraocular pressures (IOPs) or indentations at certain wound tunnel lengths.

Palanker et al<sup>9</sup> reported that three-plane laser incisions were self-sealing and watertight at physiological IOPs. It is not clear whether this applies to the incision immediately after its creation or at the end of the surgical cases following the use of the phaco handpiece and IOL insertion. Figure 4 shows the planned three-plane corneal incision and the optical coherence tomography (OCT) image of the wound 1 day after surgery.

**Effectiveness.** The effectiveness of laser limbal relaxing incisions or astigmatic keratotomy has yet to be established in the literature, although the precision of the laser in creating incisions of the precise length and depth required suggests that the procedure should be more reproducible and reliable than manual methods.

## PERSONAL EXPERIENCE

There are a few key points I would like to highlight about my experience with the LensAR Laser System, namely the easy-to-use patient interface, docking, and imaging and guidance.

**Easy-to-use patient interface.** The placement of the suction ring is straightforward, fitting on most patients quite easily. The exception is patients with very small palpebral fissures or very large brows; however, this is similar with other laser systems as well. Additionally, because the LensAR laser uses a purely liquid interface, there is no distortion or compression of the cornea, which I think is advantageous for imaging.

**Docking.** Docking with the LensAR Laser System is an interesting experience the first time it is performed, as lining up the laser and docking with the suction ring is a two-part process. The first step is completed under direct observation, using a joystick to move the laser's docking arm forward, toward the patient interface. Once the arm is in position, you turn your attention from the joystick to dual display screens, where a cross-sectional view of the x-y axis, displaying the docking arm as it is coming down toward the suction ring, and the z-axis, displaying the actual eye, are shown. These two screens are used to align the docking arm with the suction ring.

**Imaging and guidance.** Unlike the other systems that use OCT, the LensAR system uses a rotating camera with a very intense structured illumination beam of light that can easily penetrate even really dense cataracts. Because this device rotates, it takes images at four different positions and it takes two scans in each position, producing eight scans from the anterior cornea to the posterior capsule. It is astounding how this technology can image the posterior capsule so precisely, even through grade 4+ nuclear sclerosis or posterior subcapsular cataracts. Unlike OCT, these images are direct photographic images of the anterior segment, not mathematical reconstructions.

Once imaging is complete, the guidance system produces a 3-D reconstruction of the anterior and posterior corneal surfaces and the anterior and posterior lens cap-

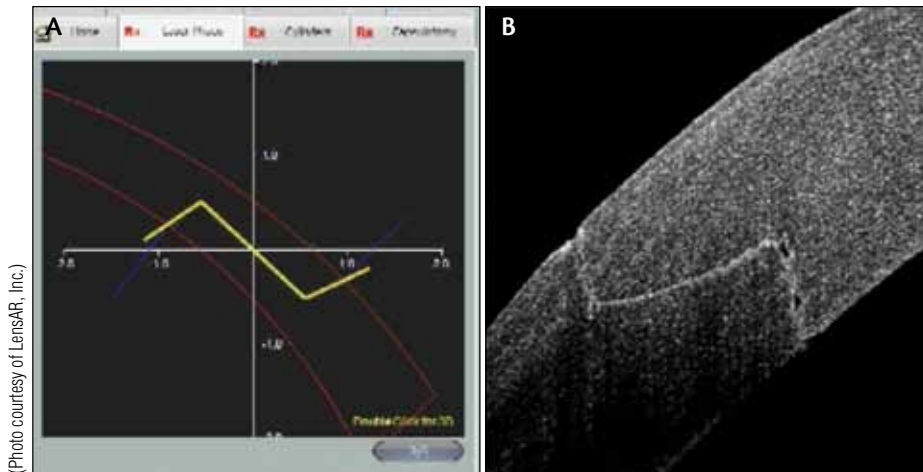


Photo courtesy of LensAR, Inc.

Figure 4. (A) Planned incision with yellow line showing path of the incision and (B) OCT of the incision after surgery.

sule. This reconstruction can be used to confirm that the treatment is appropriate. Within the following 20 seconds after the treatment is confirmed, the remainder of the procedure, including capsulotomy and fragmentation, are completed. LensAR currently does not have US Food and Drug Administration (FDA) approval for corneal incisions, but that is expected in the very near future.

### SURGICAL PEARLS FOR A NEW ERA

Having the laser complete phacofragmentation changes much of what we know about removing a cataract. All of the techniques that have been developed in the past 20 years, from divide-and-conquer to stop-and-chop, are moot now that we are entering a whole new era of cataract surgery, where the nucleus has already been fragmented by the laser prior to emulsification.

Because we are dealing with an entirely new procedure, several of the steps we are comfortable with as cataract surgeons are changing. First, in order to get an effective hydrodissection, more care needs to be taken to elevate the lens capsule and firmly inject fluid to make sure there is a good fluid wave. This should be done in several locations. If this is not done effectively, the cortex will be quite sticky, and removing the lens cortex can be the longest part of the procedure in these cases. Relearning cortical cleaving hydrodissection to make sure there is a thorough separation of the cortex from the capsule is important.

Second, I have found that using a chopper is almost optional in these procedures. With my biaxial technique, using the irrigation stream or simply injecting balanced saline solution into the nucleus directly helps to break apart the wedge-like sections of nucleus that are already separated but in juxtaposition.

Therefore, rather than hydrodelimiting the epinucleus from the nucleus, we are really hydrodelimiting the segments that have been fragmented from

each other. This facilitates phacoaspiration, and I have greatly reduced the level of ultrasound needed in these cases, if it is needed at all.

### CONCLUSION

The LensAR Laser System is not yet approved for use in the United States, and therefore my experience has all been outside the United States at this time. However, once the technology is approved and based on my current proportion of premium lens surgery procedures, I can comfortably say

that I will use laser cataract surgery in a minimum of 35% of the patients I treat. This represents patients who select a multifocal or accommodating IOL or who are having astigmatism correction with corneal relaxing incisions at the time of surgery. I do not know how financing will play out yet, but I am hopeful that I can use the LensAR Laser System in closer to 100% of cases, essentially paying for the laser with the revenue from the premium procedures I do.

*Mark Packer, MD, FACS, CPI, is a Clinical Associate Professor at the Casey Eye Institute, Department of Ophthalmology, Oregon Health & Science University, and is in private practice at Drs. Fine, Hoffman & Packer, LLC, Eugene, Oregon. He states that he is a consultant to LensAR, Inc., and to WaveTec Vision Systems, Inc. Dr. Packer may be reached at tel: +1 541 6872110; e-mail: mpacker@finemd.com.*



- Naranjo Tackman R, Villar Kuri J, Nichamin LD, Edwards K. Anterior capsulotomy with an ultrashort-pulse laser. *J Cataract Refract Surg.* 2011;37:819-824.
- Friedman NJ, Palanker DV, Schuele G, et al. Femtosecond laser capsulotomy. *J Cataract Refract Surg.* 2011;2(37):1189-1198.
- Bali SJ, Hodge C, Lawless M, et al. Early experience with the femtosecond laser for cataract surgery. *Ophthalmology.* 2012. doi: 10.1016/j.ophtha.2011.12.025.
- 510(k) K120214
- Kranitz K, Takacs A, Mihaltz K, et al. Femtosecond laser capsulotomy and manual continuous curvilinear capsulorrhexis parameters and their effects on intraocular lens centration. *J Refract Surg.* 2011. doi: 10.3928/1081597X-20110623-03.
- Nagy ZZ, Kranitz K, Takacs AI, et al. Comparison of intraocular lens decentration parameters after femtosecond and manual capsulotomies. *J Refract Surg.* 2011. doi: 10.3928/1081597X-20110607-01.
- Edwards K, Hill W, Uly H, Schneider S. Improvement in the achievement of target post-operative MRSE with laser anterior capsulotomy matches the theoretical model. *Invest Ophthalmol Vis Sci.* 2012;53:6715.
- Masket S, Sarayba M, Ignacio T, Fram N. Femtosecond laser-assisted cataract incisions: Architectural stability and reproducibility. *J Cataract Refract Surg.* 2010;36:1048-1049.
- Palanker DV, Blumenkranz MS, Andersen D, et al. Femtosecond laser-assisted cataract surgery with integrated optical coherence tomography. *Sci Translat Med.* 2010;58(1):1-9.

# Laser Cataract Surgery With the LensAR System

A potential to enhance surgical outcomes.

BY HARVEY SIY UY, MD

Laser cataract surgery is an exciting new era that brings unprecedented levels of precision, consistency, and safety to phacoemulsification. In this procedure, a noninvasive, computer-controlled, ultra-short pulse laser automatically performs the most difficult steps of cataract surgery—namely capsulorrhexis, lens fragmentation, and corneal incisions. I was attracted to this innovative treatment because of its potential to enhance refractive outcomes for my patients and its ability to help me operate on challenging cataracts. I also believed that laser cataract surgery would be easy to learn and incorporate into my practice, and I have not been disappointed.

The three main components of laser cataract surgery include the patient interface, imaging system, and laser treatment algorithms/patterns. The essential steps of the procedure are docking of the eye to the laser by means of a patient interface, imaging/biometry, surgical planning, and treatment. I selected LensAR, Inc.'s platform for laser cataract surgery because of its outstanding technical features for each of the above steps. The LensAR Laser System (Figure 1) uses a fluid-filled patient interface, 3-D high-resolution confocal structured imaging (3D-CSI) system, advanced planning software, and effective treatment algorithms.

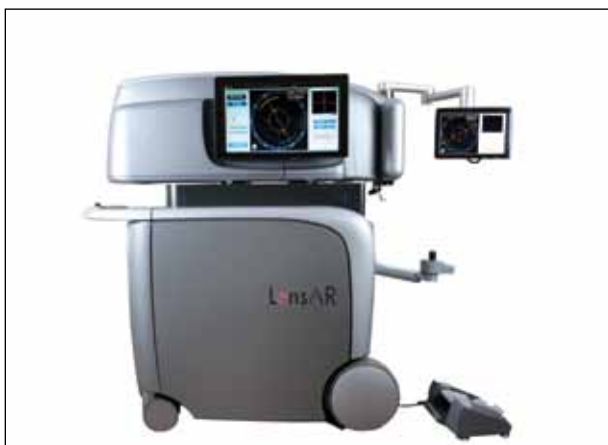

Figure 1. The LensAR machine. Note the small, mobile footprint.

## TECHNICAL FEATURES

The patient interface is easy to handle and apply, even with smaller Asian eyes. The docking system is easily controlled and attached to the interface using a docking cone (Figure 2). Low levels of suction pressure are used to stabilize the eye, which results in minimal subconjunctival hemorrhage. In the more than 700 eyes I have treated with the LensAR platform over the past 2 years, no eye developed ocular perfusion loss from suction pressure. After application of suction, the interface is filled with balanced saline solution and the laser head is docked onto the interface. Because imaging and biometry are performed through the fluid (similar to an immersion A-scan), no direct contact is made on the cornea, resulting in clear images and unimpeded laser treatment.

The LensAR Laser System has a proprietary 3D-CSI technology that produces high-resolution, Scheimpflug images of the anterior segment and cataract (Figure 3). The quality of laser cataract surgery is most dependent on the equipment's ability to precisely identify and locate ocular structures. Many eyes of patients undergoing the procedure will not be placed in a perfectly level position. This ocular tilt can lead to imaging errors that can result in gaps or attachments of the capsule. The LensAR software can detect and compensate for ocular

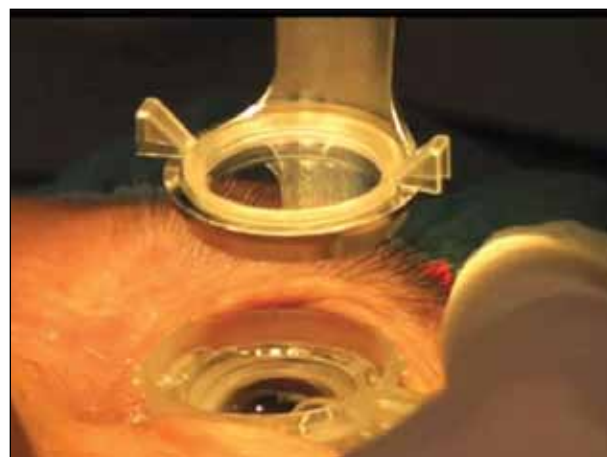

Figure 2. The disposable, lightweight, low-suction patient interface just prior to docking to laser cone.

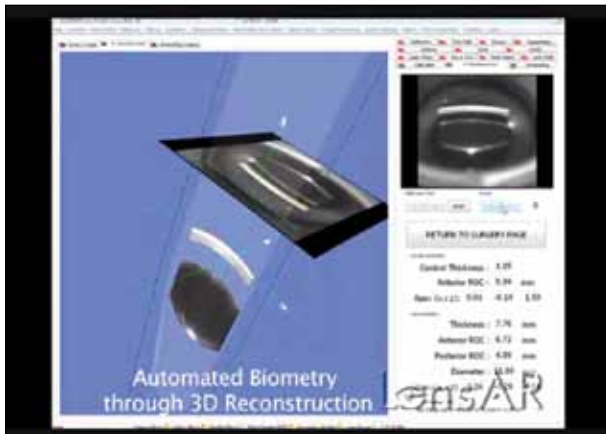


Figure 3. Screen capture of high-resolution, 3D-CSI images generated from the imaging process.

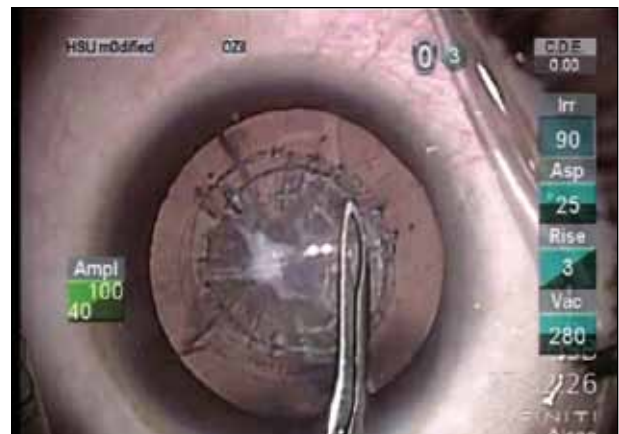

Figure 4. Laser anterior capsulotomy of a fibrotic anterior capsule.

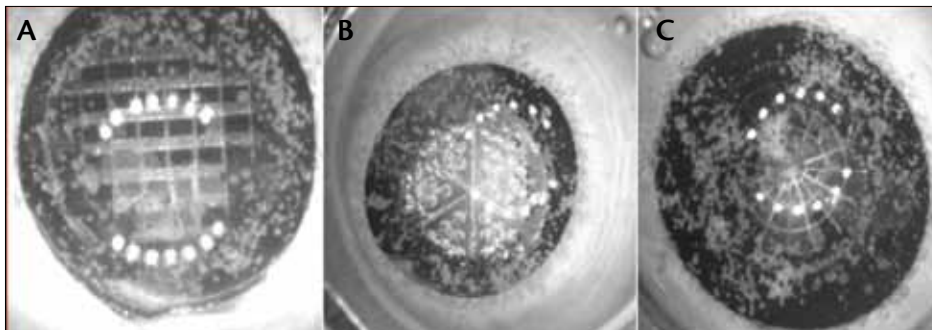


Figure 5. Various laser lens fragmentation treatment patterns/algorithm, including (A) cubes, (B) spheres, and (C) pie patterns as described by Nichamin et al.<sup>1</sup>

tilt, resulting in consistent laser anterior capsulotomy.

Using the latest software version, 48 of 48 eyes had free-floating capsules after laser anterior capsulotomy (Figure 4). We also found that these high-quality Scheimpflug images aided surgeons with the analysis of lens anatomy and in planning an appropriate surgical approach for the subsequent phacoemulsification.

After imaging, the software accurately locates the pupil and lens dimensions, and the planning software subsequently creates a treatment plan with recommended capsulotomy size, lens fragmentation diameter and depth, and treatment pattern, all while the surgeon is in full control of the procedure using an intuitive graphic user interface. Once satisfied with the treatment parameters, the laser is activated to complete the procedure.

LensAR has proven, Food and Drug Administration (FDA)-cleared treatment algorithms for laser capsulotomy and laser lens fragmentation, including patterns in cube, sphere, and pie shapes (Figure 5).<sup>1</sup> An algorithm for corneal incisions will also be introduced in the near future.

### PERSONAL EXPERIENCE

I have been using the LensAR Laser System since November 2009, and I have completed approximately 700 laser cataract

surgery and 80 lens-based presbyopia procedure. Regardless of the platform used, laser cataract surgery has a short learning curve, and many surgeons will find the steps easier to master than manual capsulorrhexis. Below I describe my experience with the essential steps of the procedure.

**Patient interface.** The most difficult step to learn in laser cataract surgery is application

of the patient interface. Care should be taken to position the patient's eye in as horizontally level a position as possible by adjusting the head portion of the bed. We learned that topical drops generally provide sufficient anesthesia for this short procedure; however, a regional block is occasionally necessary for eyes with small palpebral fissures. The docking portion of this step was easy to master using simple, ergonomic joystick controls, and our staff nurses learned to adequately assist the procedure after a handful of cases.

**Imaging/biometry.** Once docking is complete, the scanning and treatment modules are easily activated using the graphic user interface, which beautifully illustrates a 3-D construct of the lens with the superimposed treatment plan (Figure 6).

**Surgical planning and treatment.** The preferred treatment algorithm is already preprogrammed; however, the treatment pattern can be altered to adjust for specific ocular features, such as small pupils and surgeon preference.

### ELIMINATING UNPREDICTABILITY

A perfectly cut capsule eliminates the unpredictability caused by variations in capsule shape and diameter that can arise when a manual capsulorrhexis is made. A perfect capsule leads to improved refractive results,



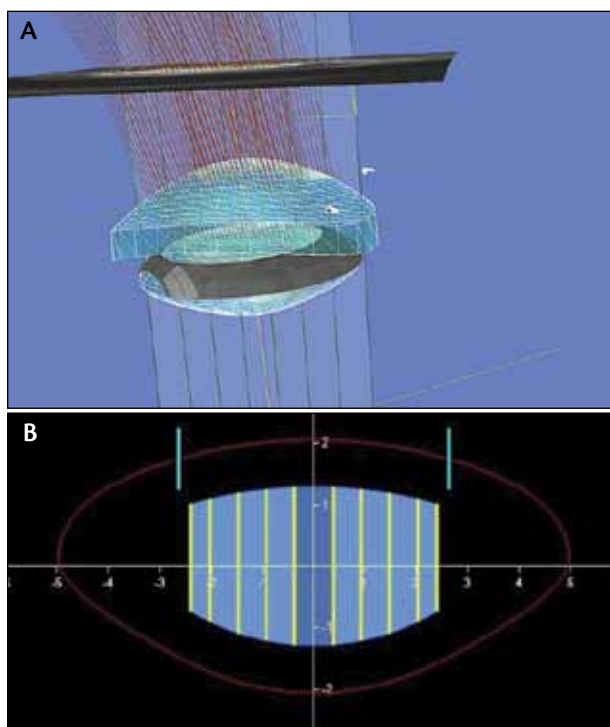


Figure 6. (A) Screen capture of 3-D reconstruction of anterior segment structures through ray tracing. (B) Screen capture of planning screen exhibiting lens construct and superimposed treatment plan.

TABLE 1. 6-MONTH MEAN ABSOLUTE DEVIATION OF THE REFRACTIVE OUTCOME VERSUS TARGET		
	Laser	Manual
Mean	0.42	0.59
SD	0.39	0.35
Median	0.38	0.50
N	249	123
P-value	<.001	

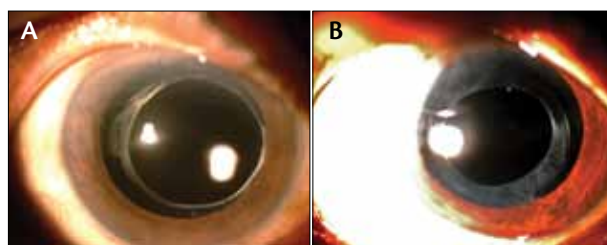


Figure 7. Slit lamp photographs of (A) laser cut anterior capsulotomy and (B) manual capsulorrhexis. Note the perfectly round laser-created capsular opening and relative absence of capsular opacification and fibrosis in Figure 7A.

and the more consistently sized, round, and capsular opening allows better positioning of the lens within the capsular bag (Figure 7). In a series of eyes followed for 6 months postoperatively, the mean absolute deviation of the refractive outcome versus target in eyes treated with laser anterior capsulotomy was  $0.42 \pm 0.39$  versus for  $0.59 \pm 0.35$  for manual capsulorrhexis eyes (Table 1). Accuracy of refractive outcomes is crucial when premium IOLs are used, and surgeons have seen, laser anterior capsulotomy can enhance a premium IOL practice.<sup>2</sup>

In another study assessing capsular strength in porcine eyes, laser-cut capsulotomies were more robust than those made with a manual capsulorrhexis technique.<sup>3</sup> This research showed that the mean force necessary to rupture the capsular edge was significantly greater with photodisruption laser, at  $177 \pm 53$  mN, versus  $125 \pm 43$  mN with manual capsulorrhexis ( $P < .05$ ). The mean capsular edge distention was significantly greater with the laser than that manual rhexis ( $7.45 \pm 0.47$  mm vs  $4.68 \pm 1.01$  mm, respectively;  $P < .001$ ).<sup>3,4</sup> In our personal experience, laser-cut capsulotomy edges are strong enough to withstand the stresses of difficult surgery, as when capsular hooks were applied to the edge of a laser-cut capsulorrhexis, the edge did not tear throughout the procedure.

Laser lens fragmentation utilizes the laser's cutting power to cut lens fibers and break up the nucleus into smaller, bite-sized pieces that are more easily removed. Clinical studies with the LensAR system have revealed that, for grade 1 cataracts, no phacoemulsification

TABLE 2. REDUCTION IN CUMULATIVE DISSIPATED ENERGY AFTER LASER PHACOFRAGMENTATION				
Treatment Groups	Grade 1 Mean (SD) N	Grade 2 Mean (SD) N	Grade 3 Mean (SD) N	Grade 4 Mean (SD) N
Laser Treatments	0.0 (0.0)	1.7 (2.0)	5.0 (6.5)	18.3 (10.1)
	1.0	10.0	15.0	13.0
Control Group	4.4 (2.4)	8.2 (6.1)	15.2 (13.0)	41.2 (24.7)
	7.0	24.0	15.0	7.0
% Difference Control vs Laser	-100.0%	-79.3%	-66.3%	-55.6%
P-value	=.002	>.001	=.041	=.052

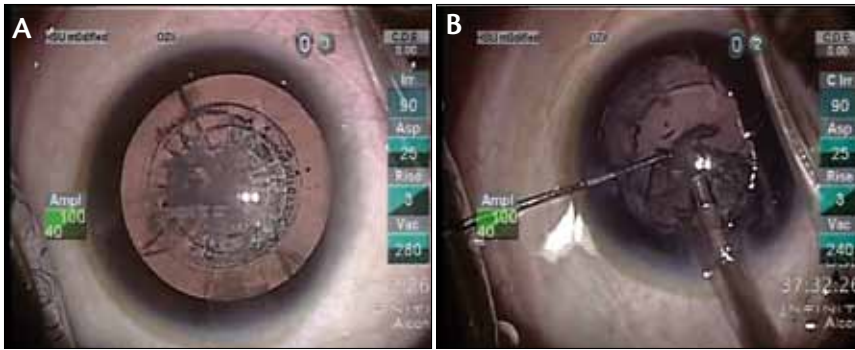


Figure 8. (A) Operating microscope view of a laser-treated grade 2 cataract. Note absence of subconjunctival hemorrhage following use of the low suction interface and pie pattern fragmentation of the lens nucleus. (B) Completion of phacoemulsification (note CDE = 0, indicating cataract removed by aspiration only without use of ultrasonic energy) is followed by aspiration of epinuclear plate and cortical material.

energy is needed, and the lens is removed purely by aspiration (100% reduction). For grade 2 to 4 cataracts, phaco energy can be reduced by 55% to 80% after laser lens fragmentation (Table 2).<sup>5</sup> Reduction in phaco energy using laser lens fragmentation can be achieved regardless of surgeon technique (eg, divide-and-conquer, stop-and-chop, prechop). These decreased levels of ultrasonic energy used during surgery can minimize the risk for endothelial damage, postoperative corneal edema, and wound burns. Additionally, the laser can be programmed to create a thin epinuclear plate between the cortex and nucleus, thus providing an extra level of protection for the posterior capsule (Figure 8).

**PRACTICE PEARLS**

The LensAR Laser System may be placed in a separate operating room or in the same room where phacoemulsification is performed. The laser procedure may be performed in either a sterile or nonsterile set-up. If nonsterile, sterile prepping and draping is performed prior to phacoemulsification. Our cycle time for conventional phacoemulsification is approximately 20 minutes; the femtosecond laser procedure takes approximately 3 minutes to complete, and transfer/transition time is about 1 minute. However, because we save time on capsulorhexis (less 30 seconds) and have faster nuclear disassembly due to laser lens fragmentation (less 1 minute), the additional time for adding the femtosecond procedure is approximately 2 minutes per case. More time savings can be obtained if the patient does not have to be transferred from one room to another.

In our set-up, the surgeon applies the patient interface and activates the laser using the footpedal control. There may be an initial increased turnover time as with adoption of any new technology, but once everyone is comfortable with the process there is no perceptible decrease in surgical turnaround time. It should also be pointed out that the machine has a small footprint and is mobile; therefore, the laser machine can easily be kept in the same room as the phaco machine.

**CONCLUSION**

Besides improved refractive outcomes, facilitated surgery, and decreased phaco energy and safety, laser cataract surgery provides other benefits such as added income and enhanced practice prestige. All of these aspects bring in referrals. Some practices are able to charge up to €1,500 for the laser procedure, adding a new revenue stream for a practice.

LensAR is my system of choice because of its unparalleled fluid-filled imaging system, which allows consistent completed capsulotomies. The laser pulse width of the LensAR is

optimized for creating capsulotomy as well as for maximizing laser lens fragmentation and reduction of phacoemulsification energy. The treatment algorithms of the LensAR Laser System are highly effective and have greatly facilitated surgery of both dense and average cataracts. This platform is ergonomic, has an easy-to-use graphic user interface, and is one of the most cost-efficient machines on the market. Promising early results have been demonstrated for accommodation restoration using the LensAR Laser System, and when this technology is developed, the machine can be used for additional functions.

More than 10,000 laser cataract surgeries have been performed worldwide using the different machines. As an increasing number of surgeons gain experience, new ways of using the technology will come to light—some surgeons find they can already do away with the use of ophthalmic viscosurgical devices for certain cataracts. As more patients become aware of the technology and its benefits, laser cataract surgery will be an essential aspect of premium refractive cataract surgery.

*Harvey Sij Uy, MD, practices at the Asian Eye Institute, Makati, Philippines. Dr. Uy states that he is a principal investigator for and has received research grant from LensAR, Inc. He may be reached at tel: +632 8982020; fax: +632 8982002; e-mail: harveyuy@yahoo.com.*



1. Nichamin LD, Uy H. Choice of fragmentation algorithm impacts the reduction in CDE during cataract surgery. Paper presented at: the Annual Meeting of the American Academy of Ophthalmology 2010; Chicago.
2. Uy HS, Hill W, Edwards KH. Refractive results after laser anterior capsulotomy. Poster presented at: the Association for Research in Vision and Ophthalmology Annual Meeting; (Poster #D634); May 5, 2011; Fort Lauderdale, Florida.
3. Frey RW, Edwards K, Naranjo Tackman R, et al. Changes in CDE with laser lens fragmentation compared with standard phacoemulsification cataract surgery. Invest Ophthalmol Vis Sci. 2010;51:E-Abstract 5418.
4. Tackman RN, Kuri JV, Nichamin LD, Edwards K. Anterior capsulotomy with an ultrashort-pulse laser. J Cataract Refrac Surg. 2011;37:819-824.
5. Edwards KH, Frey RW, Tackman RN, et al. Clinical outcomes following laser cataract surgery. Invest Ophthalmol Vis Sci. 2010;51:E-Abstract 5394.

# Learning the LensAR Approach to Femtosecond Laser Cataract Surgery

An exciting process, still in progress.

BY MIGUEL A. ZATO, MD, PhD; AND ALFONSO ARIAS, MD, PhD

Recently, laser cataract surgery has generated a great deal of interest among surgeons around the world and has the significant potential to produce safe, reliable, and optimized postoperative outcomes for our patients. Early studies have demonstrated that cataract procedures performed with a femtosecond laser use less phaco energy across all grades of nuclear densities<sup>1</sup> and that they increase refractive accuracy.<sup>2</sup>

Like many of our colleagues, we were interested in gaining firsthand experience with this new surgical paradigm and jumped at the chance to train with one of the most versatile systems available today. Below we describe our short-term experience with laser cataract surgery, which occurred during a 3-day visit to the Eye Institute Sacro Cuore in Lima, Peru in March 2012, and how I envision learning the LensAR approach will improve my outcomes with regard to creating corneal incisions, performing anterior capsulotomy, and fragmenting the lens with high efficacy and accuracy.

## IMAGING TECHNOLOGY

One of the most notable differences between the available laser cataract surgery systems is the method of imaging and subsequent ranging for the desired treatment. Currently, there is emphasis on the use of image-guided treatments. The LenSx Laser (Alcon Laboratories, Inc.) and the Victus Femtosecond Laser Platform (Bausch + Lomb/Technolas Perfect Vision GmbH) use optical coherence tomography (OCT) to assess the location of intraocular structures. With these systems, the surgeon must inspect the image and choose the location of the incisions while the patient is under applanation. The Catalys Precision Laser System (OptiMedica Corp.) also uses OCT, but this system has automated the interpretation and treatment planning.

One of the ways LensAR sets itself apart from these other technologies is in its approach to imaging. This laser system uses proprietary technology, called 3-D

confocal structured illumination (3D-CSI), to image the entire anterior segment of the eye. Because the unit uses a Scheimpflug imaging technique to enhance the depth of field of the image capture, it provides a high-resolution image from the anterior portion of the cornea to the posterior capsule in a single image. The excellent contrast of the image allows the software to automatically detect the edges of all of the important structures of the eye and then plan the customized treatment for capsulotomy and lens fragmentation pattern.<sup>3-5</sup>

## PERSONAL OBSERVATIONS

Over this short period, we watched surgeons who have experience with laser cataract surgery operate on cataracts with hard and soft nuclei, we performed our first laser cataract surgery procedures, and we confirmed numerous advantages of incorporating a laser surgical technique to cataract procedures. The advantages, as we see it, are that laser cataract surgery can be used to:

- Create incisions and spaces of different shapes, at a desired depth;
- Perform precise circular capsulotomies with an adjustable diameter; and
- Fragment the lens using precise cuts in a targeted area, without damaging the surrounding tissue.<sup>1</sup>

Our surgical learning curve for laser cataract surgery was shorter than our learning curves with other refractive laser procedures, such as femtosecond LASIK and/or PRK. Therefore, assuming that the surgeon has experience with other corneal refractive laser procedures, we have concluded that there are only three new components the cataract surgeon must become familiar with for laser cataract surgery specifically: applying the suction ring, docking the fluid-filled patient interface device, and performing eye manipulations.

Using the LensAR laser approach to cataract surgery, there is no requirement to understand and manage complex nomograms, and therefore we were able to

devise and implement a standardized surgical procedure rather easily. Within our first few procedures, we became comfortable using the various tools of the laser system, including its:

- Compact, no corneal contact, fluid-filled patient interface, with limited intraocular pressure (IOP) rise, no imaging artifacts to disrupt laser placement, and no corneal distortion during the eye treatment;
- High-resolution Scheimpflug imaging system, allowing automated surface detection and 3-D reconstruction for further refinements in treatment options; and
- Automatic detection and correction for lens tilt, thus enhancing surgical safety, effectiveness, and efficiency.

With these tools, we were able to enhance our refractive outcomes and perform predictable effective lens position (ELP) calculations; provide better results and optimize target refractions with better centration and no lens tilt; and significantly reduce ultrasound energy, thus improving endothelial health and promoting faster visual recovery.

In total, 64 laser cataract surgery procedures were performed during this week in Peru. For each, the capsulotomy was preoperatively planned for 5.0 mm, and a specific lens fragmentation pattern (a combination of radial and concentric cuts called *pie pattern*) was selected. In all the cataract cases surgically treated with this femtosecond laser technology, the procedure was completed successfully, without suction loss or broken posterior capsules, even in cases with hard nuclei.

## TAKE-HOME PEARLS

It is important to mention that the laser cataract procedure requires active patient cooperation. To achieve and maintain correct pupil centration with the LensAR Laser System, the patient must fixate on a microscope light during the docking procedure and also during a maximum of 40 seconds of suction time, when the laser is executing the lens fragmentation and the capsulotomy portions of the procedure.

In our early experience with laser cataract surgery, we learned that the cornea can become increasingly blurred during treatment (because of plasma bubbles running into the anterior chamber). One thing that we think will be beneficial in our own practice is to tell patients that this blurriness is normal during surgery. We also plan to instruct patients to continue looking straight ahead, even if the light becomes blurry, and encourage them to avoid moving their eyes. When patients cooperate during this time, the risk of suction loss is minimized.

After learning the LensAR approach to laser cataract surgery, we believe that the preciseness of capsulotomy creation and placement, as well as the versatility of incision creation and placement, will improve our surgical outcomes. We are also excited to have the opportunity to use the LensAR to fragment nuclear pieces using precise cuts in a target area, thus allowing us to reduce phaco energy and perform a safer procedure.

## CONCLUSION

In our opinion, femtosecond laser technology for cataract surgery is the most significant development in refractive crystalline and cataract surgery since the introduction of phacoemulsification. This technique has the potential to become the gold standard of cataract surgery in the near future, as our early experience and the early experience of others suggest it is more precise and accurate than conventional phacoemulsification. Additionally, the LensAR laser platform, specifically, provides the combined advantages of femtosecond laser surgery and high-resolution 3-D imaging to produce excellent efficacy and accuracy with minimal risk of complications.

The biggest obstacle that all lasers for cataract surgery face is the same: How will it be paid for? A femtosecond laser platform is a major capital investment and, therefore, much care should be taken when deciding when to purchase this technology. Based on reported studies, surgeons who adopt laser cataract surgery will achieve improved visual outcomes as well as increased safety, although it is probably too early to elucidate the impact that this technology will have on patient care.

*Miguel A. Zato, MD, PhD, is a Head Professor of Ophthalmology, Hospital de la Zarzuela, in Madrid, Spain. Dr. Zato states that he has no financial interest in the products or companies mentioned. He may be reached at tel: +34 913078942; e-mail: incivi@incivi.com.*

*Alfonso Arias, MD, PhD, is a Head Professor of Ophthalmology, Fundacion Alcorcon, in Madrid, Spain. Dr. Arias states that he has no financial interest in the products or companies mentioned.*

1. He L, Sheehy K, Culbertson W. Femtosecond laser-assisted cataract surgery. *Curr Opin Ophthalmol.* 2011;22(1):43-52.
2. Naranjo-Tackman R. How a femtosecond laser increases safety and precision in cataract surgery? *Curr Opin Ophthalmol.* 2011;22(1):53-57.
3. Slade SG. Comparison of effective lens position manual vs femtosecond laser. Paper presented at: the ASCRS Symposium on Cataract, IOL and Refractive Surgery; March 25-29 2011; San Diego.
4. Vukich JA, Culbertson WW, Battle JF, Seibel J, et al. Characterization of femtosecond anterior capsulotomies. Paper presented at: the ASCRS Symposium on Cataract, IOL and Refractive Surgery; March 25-29 2011; San Diego.
5. Frey RW, Teuma EV, O'Suilleabhain D. Evaluation of the mechanical properties of the crystalline lens capsule following photodisruption capsulotomy and continuous curvilinear capsulorhexis. Poster Presented at: the Annual Meeting of the Association for Research in Vision and Ophthalmology; April 29 2011; Fort Lauderdale, Florida.

# First Impression of Laser Cataract Surgery

After attending LensAR training in Peru, I am convinced this technique is the next great step in cataract surgery.

BY DETLEF HOLLAND, MD

After 3 days of training on the LensAR Laser System (LensAR, Inc.) at the Instituto de Ojos Sacro Cuore in Lima, Peru, my view on the future of cataract surgery has drastically changed. Before I saw the efficacy of this laser platform and performed surgery on my own, I figured that laser cataract surgery would be used only in the premium IOL sector, in patients with soft cataracts. Now after this short but memorable experience in Peru (Figure 1), I am not only convinced that laser cataract surgery will have a large impact on our ability to perform precise cataract surgery, but I am anxious to incorporate this modality into my own practice. Although we know that laser cataract surgery is still at the beginning of its development, the techniques surgeons have thus far mastered are at the highest level available today.

## SAFETY FIRST

When embarking on a new kind of surgical technique or procedure, the first and foremost concern is safety. In the field of cataract surgery, one of the most important elements of safety is the accurate measurement of the lens. This is no different for laser cataract surgery. Compared with other femtosecond laser platforms on the market for cataract surgery, the advantage of the LensAR Laser System is that it uses a 3-D confocal structured imaging (3D-CSI) system that works with a Scheimpflug camera. With this approach to imaging the ocular structure, interpolation and extrapolation, two factors that are necessary for reconstruction, are reduced. Additionally, eight extremely rapid scans are taken to measure the cornea, the depth of the anterior chamber, and the thickness of the lens with anterior and posterior curvatures.

The LensAR 3D-CSI software can also detect tilt over the lens, subsequently accounting for it in the planned treatment. In this and other ways, the surgeon can rely on the LensAR Laser System to produce safe and reliable outcomes in all cases, despite the individual status of the eye to be treated. Additionally, the surgeon can select the size of the rhexis and its position. If the pupil is smaller than the planned size of the rhexis, its diameter will be adapted automatically. A 1-mm safety zone toward the posterior capsule is used in the fragmentation plan to minimize the risk of firing into the capsule. So far in my experience, I have only performed rhexis and lens fragmentation with the laser; the LensAR system, however,

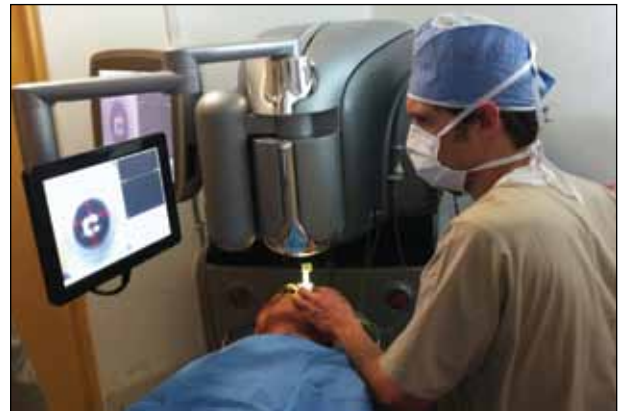

Figure 1. Dr. Holland performs one of his first laser cataract surgery cases with the LensAR Laser System.

will soon be able to plan and perform clear corneal incisions and limbal relaxing incisions as well.

Docking is easy to learn, especially for surgeons who have worked with laser refractive surgery platforms. The only difficulty I had was in eyes with narrow lid margins. Due to the fluid-filled patient interface device, corneal appplanation is not performed. This, in my opinion, is a great advantage because appplanation can cause folds in the cornea that can interfere with the laser beam. In each and every case the suction level was low, and even during our short learning period it took no longer than 5 minutes for both measuring and treating.

## PERSONAL EXPERIENCE

There is a learning curve for laser cataract surgery, and with the LensAR Laser System this mostly concerns the docking technique. In the five cases I performed while in Peru, I was continually impressed with how fast and how precise 3-D reconstruction of the anterior segment was. All patients tolerated the suction ring, as well as its docking, and had no problems with the treatment being done under topical anaesthesia.

During lens extraction in these cases, I had a totally new view of the eye. Creating a laser capsulotomy and using laser lens fragmentation is unique; in these cases, the lens looks quite different and the surgeon can truly see the architecture of the fragmented lens. In a few cases, however, I saw large gas bubbles within the capsular bag and

*(Continued on page 15)*

# Laser Cataract Surgery and Phaco Time

With the latest software, surgeons can reduce effective phaco time and increase surgical outcomes.

BY SUNIL SHAH, FRCOPHTH, FRCS(Ed), FBCLA

Cataract surgery is the most commonly performed surgical procedure in the world. Over the history of the procedure, which dates back more than 2,000 years, various innovations have helped surgeons enhance outcomes and increase safety. In the more recent history of cataract surgery, the introductions of two innovations, IOLs and phacoemulsification, were the first big advancements that captivated and motivated surgeons to perform flawless surgeries. Just as these innovations sparked a renewed interest in the importance of surgical techniques, we are once again witnessing a revival of the importance of surgical technique—this time for those advanced techniques afforded with laser cataract surgery.

I am one of the lucky surgeons who has had limited initial experience with a new laser cataract surgery platform. Over the course of a few procedures done on animal eyes with a prototype laser platform for cataract surgery as well as experience in a limited number of human eyes, I have already begun to believe in the power of laser cataract surgery. Yes, modern cataract surgery using a manual technique for capsulorrhexis, lens fragmentation, and emulsification is safe and effective. Yes, modern cataract surgery utilizes a plethora of tools and techniques that produce predictable results. However, I believe that laser cataract surgery is the next step—the final step—in our quest for perfect surgical results.

By eliminating the surgeon factor in such delicate steps of cataract surgery, postoperative results are not just predictable but reproducible every time.

I recently traveled to Lima, Peru to gain experience with LensAR's laser cataract surgery platform. Over the course of 3 days, I performed my first surgery on five eyes with a laser system and with phacoemulsification equipment that I was not accustomed to, in an operating room that was not my own. Even in this unfamiliar setting, with new equipment and a learning curve for a new procedure, I was able to perform cataract surgeries with reproducible (and excellent) results.

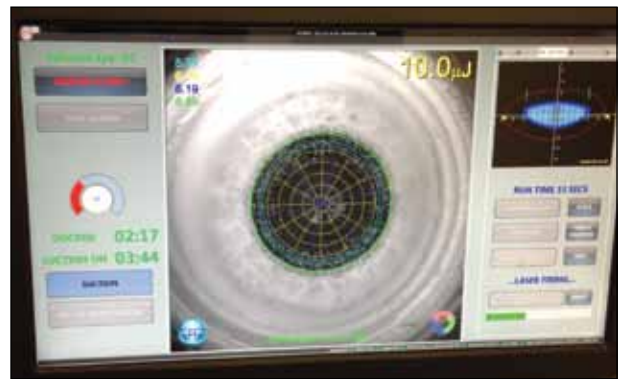


Figure 1. Laser phacoemulsification with the LensAR Laser System using a pie-shaped pattern.

## PERSONAL EXPERIENCE

One of the nice things about transitioning to laser cataract surgery is that the procedure is very intuitive and therefore the learning curve is minimal. While I was in Peru, not only did I perform my first laser cataract surgery cases in human eyes, but I also witnessed two other European surgeons and six American surgeons use the LensAR Laser System for the first time. None of us had any significant difficulty learning the procedure, and we all managed to get a good image and perform surgery with ease at first attempt. In fact, there were numerous comments from some of the surgeons about never having done surgery with their hands on their laps.

The learning curve for the phacoemulsification portion of the procedure may be a little longer, as certain modifications must be made to use phaco settings effectively. By my third case, however, I was able to increase vacuum and reduce phaco power to optimize my outcomes. By this time, the entire laser procedure, from start to finish, lasted 3.5 minutes. During my fifth and final laser cataract surgery procedure in Peru, which was on a grade 4 cataract, I only needed 3 seconds of phacoemulsification to complete nuclear removal—and this was on a phaco system with settings I kept adjusting and in an operating room that I was not used to.

## EXPECT EXCELLENT RESULTS

When I went to Peru, I was not absolutely sure what to expect and I was skeptical to believe the results I had heard from my colleagues who had experience with this technology. I also heard about the difficulty with some other femtosecond systems of imaging the posterior capsule and the risk of inadvertently lasering the posterior capsule, and I was anxious that the same would be true with the LensAR Laser System.

However, I was able to find out firsthand just how flawlessly the LensAR Laser System works for cataract surgery. The machine was very easy to use, and it functioned perfectly every time with every surgeon. The LensAR's 3-D confocal structured imaging (3D-CSI) system was very clear, and the automatic registration of the position of the capsule was not only quick but impressive. The software also accounts for the tilt of the image and lens, which is advantageous.

I was impressed by the perfectly circular capsulorrhexis with usually a free cap and how lens fragmentation significantly softened the lens (Figure 1) and made the phaco much easier. I suspect these advantages will lead to faster visual recovery and more predictable results for my patients, which have been shown in preliminary (unpublished) studies. Now I know to expect excellent results with the LensAR Laser System.

## CONCLUSION

Although I have not quite worked out the logistics of how I will use the LensAR Laser System in my practice, I am anxious to incorporate this technology in whatever workflow I decide is best for my practice. As I see it, cataract surgery would be an even quicker procedure than we are used to today if one surgeon performed the laser portion and another the phacoemulsification portion of the procedure. It may be nice to strive toward that, but initially I think I will work out how to perform the procedure from start to finish myself. I am interested to try completing a handful of lasers followed by the phacoemulsification procedures in these same eyes. Whatever process I choose, laser cataract surgery with the LensAR Laser System is an exciting prospect and I believe it is here to stay.

*Sunil Shah, FRCOphth, FRCS(Ed), FBCLA, is a Honorary Professor at the School of Biomedical Sciences, University of Ulster, Coleraine, Northern Ireland; Visiting Professor at the School of Life & Health Sciences, Aston University, Birmingham, United Kingdom; Director, Midland Eye Institute, Solihull, United Kingdom; and Consultant Ophthalmic Surgeon, Birmingham & Midland Eye Centre, Birmingham, United Kingdom. Professor Shah states that he is a consultant to Topcon Europe. He may be reached at tel: +44 1217112020; fax: +44 1217114040; e-mail: sunilshah@doctors.net.uk.*



*(Continued from page 13)*

the red reflex was missing.

With the help of the LensAR Laser System, the capsulorrhexis is absolutely round and well centered, with very sharp edges. In most cases, the rhexis was free-floating and could be lifted by using only an ophthalmic viscosurgical device and removed with a forceps. The appearance of hydrodissection is different to what I was used to—I found it to be hardly noticeable with laser cataract surgery—and I would recommend to perform hydrodissection in a careful but intensive manner.

## FASTER SURGERY

I was able to reduce my typical phaco time, even in grade 3 to 4 cataracts. With standard cataract surgery, my effective phaco time is approximately 7 seconds; with laser cataract surgery, effective phaco time is closer to 3 seconds. Cracking and chopping of the lens is also much easier with the LensAR Laser System, as we are used to performing nuclear disassembly with a phaco chopper. Using the holdability of the phaco system with very high vacuum, emulsification of the lens can be performed with the shortest phaco time possible.

In my small series of eyes, for which a short learning curve was observed, I was impressed with the reduced phaco time. I believe new phaco techniques will be developed for laser cataract surgery compared with the standard phacoemulsification techniques we are currently using. This will result in further reduction of phaco time, less endothelial cell loss, and increased safety. The precise size and location of the rhexis will also improve safety, refractive results, and visual quality.

## SUMMARY

Using the LensAR Laser System for the first time in March 2012, I was easily convinced that laser cataract surgery is the next great step in cataract surgery. When combined with phacoemulsification and microincision cataract surgery, this new technique provides improved safety and precision of our surgical procedure.

One of the nice things is that the learning curve for laser cataract surgery seems to be quite short, meaning ease of transition in our practices. I am also looking forward to experimenting with new phaco techniques, as I believe this will lead to further improvements in postoperative outcomes. Such techniques should mean gentler lens extraction and further reduction of phaco time. I am looking forward to adding the LensAR Laser System into my practice in northern Germany this summer. ■

*Detlef Holland, MD, is a cataract and refractive surgeon at the Augenklinik Bellevue, Kiel, Germany. Dr. Holland states that he has no financial interest in the products or companies mentioned. He may be reached at e-mail: d.holland@augenklinik-bellevue.de.*



**Distributed by:**

**IQ Medical Pty Ltd**

2/86 Mary Street, Unley SA 5061

**Phone** (08) 8357 8022

**Email** [sales@iqmedical.com.au](mailto:sales@iqmedical.com.au)

**Web** [www.iqmedical.com.au](http://www.iqmedical.com.au)

**Cataract & Refractive Surgery**  
**EUROPE** **TODAY**